

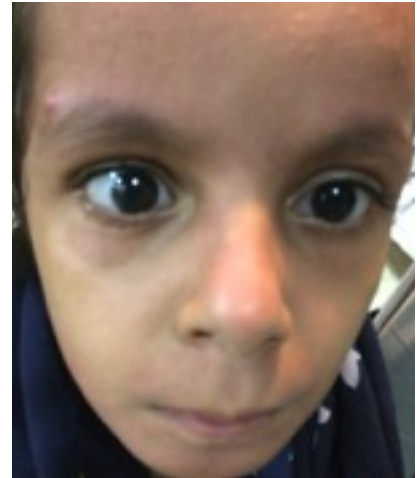
TUTORIAL 3:

These 2 patients came with prominent eye for the last 4-6 months.

A: A kid, 8 years old, c/o headache and difficulty to concentrate in studies.

O/E: Slight lid retraction, ocular motility normal. His VA: 6/6 either eye. Pupils were brisk. Color Vision Normal. Slightly congested optic discs and some blurring of nasal margins.

Plz give your Provisional diagnosis and management plan.



B: This 34 years old lady with prominent right eye since 6 months.

O/E: VA: 6/6, pupils, brisk. Slight reduction in elevation Right eye and lid lag. Plz give your diagnosis, and management plan.

